

# Outcome of Hemi Arthroplasty Using Cemented Bipolar Prosthesis in Neglected Fracture Neck of Femur in Elderly: A Study of 1156 Cases

Md. Munzur Rahman<sup>1\*</sup>, Dr. Md. Hassan Jamil Hedyatullah<sup>2</sup>, Dr. Abul Kalam Azad<sup>3</sup>, Hasibul Hasan<sup>4</sup>

<sup>1,2</sup>Assistant Professor, Department of Orthopaedic Surgery, Rajshahi Medical College, Rajshahi, Bangladesh

<sup>3</sup>Junior Consultant (Ortho Surgery), Sadar Hospital, Netrakona, Bangladesh

<sup>4</sup>Department of applied Nutrition and Food Technology, Islamic University, Bangladesh

DOI: [10.36348/sjbr.2021.v06i05.007](https://doi.org/10.36348/sjbr.2021.v06i05.007)

| Received: 06.04.2021 | Accepted: 10.05.2021 | Published: 14.05.2021

\*Corresponding author: Md. Munzur Rahman

## Abstract

**Introduction:** A much controversy exists regarding treatment of neck of femur fractures in elderly. Currently, choices available options for an Orthopaedic surgeon for treating these fractures in elderly are Canulated cancellous screw fixation, Girdstone, unipolar hemiarthroplasty, bipolar hemiarthroplasty and total hip arthroplasty. One of the most common treatments of Garden type-III & IV fracture of femoral neck in elderly in low- and middle-income countries is bipolar hemiarthroplasty. This study was conducted to evaluate functional outcome of fracture neck of femur treated with cemented bipolar hemiarthroplasty in elderly. **Materials and Methods:** Multicentered based non randomized quasi experimental prospective study was performed in Rajshahi Medical College Hospital, Dhaka Medical College Hospital and Spine & Orthopaedic Specialized Centre, Rajshahi, Bangladesh from January 2010 to December 2019. Total number of patients n=1156 with fracture neck of femur were operated with cemented bi-polar prosthesis of femoral component and their functional outcomes were assessed on the basis of modified Harris Hip Score. **Results:** At the end of 10 year after surgery, the functional results were analyzed by SPSS 18.0. All patients were in the age group of 50-85 years with mean age of 62.09 years for males and 69.42 years for females. 48% percent of the patients had sub-capital fracture radiologically, while 52% had Transcervical. In 68% of cases, the mode of injury was trivial trauma. Complications observed were superficial surgical site infection (1%), affected sided mild hip pain (15%), LLD < 1.25 cm of 0.01% and post-operative dislocation within 3 months in another patient. There were 64% excellent results, 28% good results and 8% fair results. No poor results were found in our study. **Conclusions:** Elderly neglected patients with displaced fracture of neck femur are able to ambulate early after Cemented bipolar hemiarthroplasty. The complication rate is very low and pre injury functional status is restored in majority of patients.

**Keywords:** Hemi replacement arthroplasty, cemented bipolar prosthesis, fracture neck femur.

**Copyright © 2021 The Author(s):** This is an open-access article distributed under the terms of the Creative Commons Attribution 4.0 International License (CC BY-NC 4.0) which permits unrestricted use, distribution, and reproduction in any medium for non-commercial use provided the original author and source are credited.

## INTRODUCTION

Fracture of the neck femur remains the unsolved fracture as far as treatment and results are concerned. In geriatric population femoral neck fractures is one of the most common injuries, typically results from low energy trivial falls and may be associated with osteoporosis. Prevalence of these fractures has further increased with improvement in life expectancy. Their complications cause major permanent disability in the elderly patients and are a major cause of death in the elderly. Sir Watson Jones considered this fracture to be the terminal event in the life of feeble and fragile patients who used to die of cardiac, pulmonary, and renal complications aggravated by immobilization and recumbency. The goal of

treatment of these fractures is restoration of pre-fracture function without associated morbidity. But much controversy exists regarding treatment in elderly patients [1, 2, 4]. Open reduction and internal fixation of these fractures in elderly has poor outcome because of high rate of nonunion and avascular necrosis [2, 3]. Introduction of single piece unipolar metal prosthesis in 1950's, to replace the femoral Head offered an alternative form of treatment [5, 6]. The problems encountered were acetabular erosion and loosening of stem giving rise to pain. In spite of these, superiority of prosthetic replacement over internal fixation was well established [8]. There is controversy at present whether to do hemiarthroplasty, bipolar or otherwise or primary THR in these cases. One of the aims of this study is to see whether bipolar hemiarthroplasty meets desired end

result. As the bipolar hemiarthroplasty being quicker leading to lesser morbidity and low rate of dislocation which is quite common after primary THR in fracture of neck femur. Bateman in 1974 introduced the prosthesis which had mobile head element and had additional head surface to allow movement within the acetabulum [7]. This led to reduced wear of acetabular surface and the prosthesis. The main aim to reduce immobilization and make patient walk early, with improved survival of implant is clearly met by this bipolar prosthesis. The aim of this case series is to describe the operative management and outcomes from the largest published series to date of patients with hemiarthroplasties of the hip and to out-line our treatment strategy.

### AIMS AND OBJECTIVES

1. To study functional outcome in patients treated with cemented bipolar prosthesis for femoral neck fracture.
2. To study the associated complications.

### MATERIALS AND METHODS

Multicentered based non randomized quasi experimental prospective study was performed in Rajshahi Medical College Hospital, Dhaka Medical College Hospital and Spine & Orthopaedic Specialized Centre, Rajshahi, Bangladesh from January 2010 to December 2019. Total number of patients n=1156 with fracture neck of femur were operated with cemented bipolar prosthesis of femoral component and their functional outcomes were assessed on the basis of modified Harris Hip Score. On presenting to the hospital at Out Patient Department (O.P.D.), Indoor patient department and casualty, all patients were managed according to the ATLS guideline, subjected to thorough clinical examination which included tenderness site, ecchymosis, limb length discrepancy, attitude of limb and associated skeletal injuries were also noted. Quick systemic examination was done to assess cardio-vascular, respiratory, and central nervous system. Vital signs i.e. pulse, blood pressure, and respiratory rate were noted. If the patients on presentation, due to associated injuries were found to be hemodynamically unstable, resuscitation was carried out till patient became hemodynamically stable. After roentgenographic evaluation patient were admitted and traction was given on affected side. Traction was given with the aim to decrease pain and spasm and to maintain limb length. While on traction, the patients were encouraged to do active gluteal exercises. This was with the aim to prevent bed sore and to keep the glutei in good functional condition as they will be required later on postoperatively for walking. Active quadriceps exercises were also taught.

Patient with systemic diseases like hypertension and diabetes mellitus were treated as per physician's advice. Necessary investigations for surgical fitness were conducted. Patients were operated as soon as the fitness for anesthesia was obtained.

Shaving of local parts was done the day before the surgery. Local parts were cleaned and scrubbed on previous night and repeated on early morning on the day of surgery. Patients were operated under spinal anesthesia or combined spinal plus epidural anesthesia or general anesthesia. Patients were given injection cefotaxime 1 gm intravenously 30 minutes before incision. Lateral position on a straight table. Patient was anchored firmly using side supports to the table. All patients were operated using Modified Gibson's approach in lateral position. The patient was immobilized were given abduction splint postoperatively to take care adduction of limb. Intravenous antibiotics were given for first 6 days followed by oral antibiotics for 8 days. A post-operative X-ray was advised when the patient could be shifted comfortably, usually after 48 hours of surgery. Negative suction drain was removed after 48 hours of surgery, when the first dressing was performed. Sutures were removed on 14th day after surgery. Under normal circumstances, with the patient being stable postoperatively, static and active quadriceps exercise were advised on the same evening within the limits of comfort followed by high sitting on the 2nd postoperative day. Depending upon the pain and reliance of the patient to follow our advice, patients were made to walk full weight bearing with the support of walker on 3rd post-operative day and with walking stick in opposite hand depending on patient's comfort. The patients were discharged with walking stick mobilization and advised regarding the following:

- Not to squat.
- Not to sit cross legged.
- Not to do active straight leg rising.
- To use stick in opposite hand while walking.
- To do quadriceps exercises.

The patients were followed up post-surgery at the end of one month, three months and then six months. At each follow up patients were assessed clinically and functionally for pain, limp, support and range of movements. Radiological assessment was done to know loosening of implant, erosion of acetabulum, protrusion, stem position, subsidence of stem and osteolysis around stem. At final follow up results were rated as excellent, good, fair or poor according to modified Harris Hip Score.

### RESULTS

Minimum follow up of 12 months up to 10 years was taken in the final reporting of the results. All patients were in the age group of 50-85 years with mean age of 66.2 years (62.09 years for males and 69.42 years for females). We had 22 males and 28 females (M: F ratio was 1:1.27). All females in our study were housewives (56%). Most fractures of femoral neck (68%) occurred following low velocity trauma, largely due to osteoporotic bone in elderly. Patients sustained fracture following low velocity trauma such as fall from

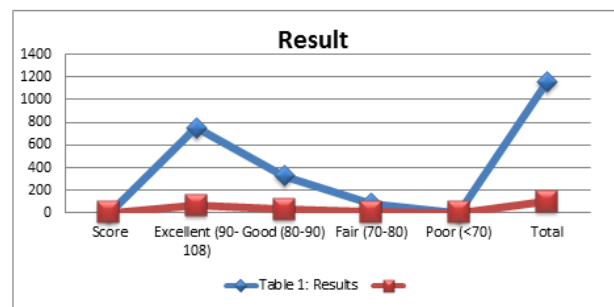
bicycle/stairs fall from standing height or slippage while walking. 32% of fractures occurred following high velocity trauma like vehicular accident. Out of 1156 cases, 652 had right side and 504 had left side involvement. Thus the ratio of right to left was 1.27:1. There was no associated injury in any patient except 1 patient who had wound over ipsilateral leg for which debridement and suturing was done. Sixteen patients had associated medical illness, amongst which Hypertension was the commonest (16%). 48% percent of the patients had sub capital fracture radiologically, while 52% had Transcervical.

43 mm was the commonest size of the prosthesis used in our study [Table 3]. In males 45 mm was the commonest size used while in females 41 mm was used most frequently. In 44% of the cases the stem was in neutral position while in 16% of cases the stem was in varus position [Table 4]. In 40% of cases stem was in valgus. 1018 patients (88%) were mobilized with the help of walker by 3rd post-operative day. 138 patients were not mobilized early due to systemic illness and age related problems. 58% patients were discharged within 10 days after clean dressing, adequate mobilization, proper instruction and follow up in O.P.D. for suture removal. 10% patients stayed for more than 15 days in hospital due to delay in surgery, associated injuries, systemic diseases and superficial wound infection. No cases of nerve injury, vascular injury, deep vein thrombosis or pulmonary embolism were noted in our series. In our series 57 patients (5%) had superficial wound infection. Patient developed signs of infection in the first week of operation which resolved by change in antibiotics according to culture sensitivity. Other patient required debridement of wound. 57 patients (5%) had dislocation in first week after operation for which closed reduction under anesthesia was done. 52% of patients had no pain at final follow up. 48% experienced slight pain which amounted to occasional ache or awareness of pain of low grade with no compromise in activity. 72% of patients had no limp while 28% patients experienced mild to moderate limp while walking. In our study we advised the patient to use a cane in the opposite hand but most of patients did not use cane for daily activity as they could comfortably walk without support. Majority of patients (84%) did not require any form of support for routine activities. 93 patients (8%) required continuous support due to pain and old age related problems. 93 patients (8%) were using cane only for long walk. Majority of the patients (96%) were able to walk up to 1 kilometer or more following operation. Some of the remaining had limited walking distance due to pain, old age and associated condition like osteoarthritis. Most of the patients were able to use stairs, where appropriate footwear, sit comfortably and were able to enter public transport. Thus in 84% of the patients there was no limb length discrepancy. No case showed limb shortening while 16% showed limb lengthening. There were no cases of aseptic loosening,

infection or stem failure. There was no change in the position of stem at the end of follow up period as compared to immediate post-operative radiograph [Table 4]. No case of prosthesis dislocation, acetabular erosion or protrusion was noted in our study. No deformity was found in any of the cases. In 92% of cases the flexion was more than 100° and 76% patients had than 10° extension was possible. In 88% of cases the abduction was greater than 30°. In 92% cases adduction was more than 20°. In 84% of cases External Rotation was more than 30°. In 52% of cases, the internal rotation was more than 20°. Results were graded according. There were 64% excellent results, 28% good results and 8% fair results. No poor results were found in our study [Table 1]. The study showed excellent outcome even in patients more than 70 years of age. Out of 138 patients with excellent results 7 patients were above 108 years of age.

**Table-1: Results**

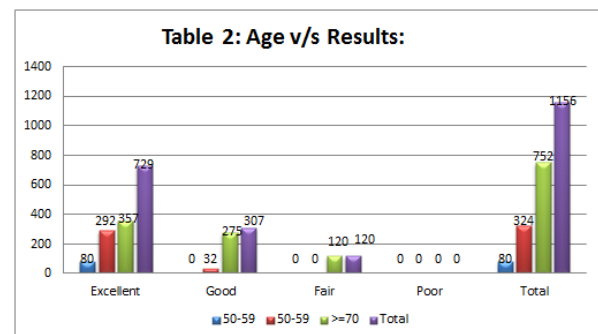
Score	No. of Cases	Percentage (%)
Excellent (90-108)	752	64
Good (80-90)	324	28
Fair (70-80)	80	7
Poor (<70)	0	0
Total	1156	100



**Fig-1 Result**

**Table-2: Age v/s Results**

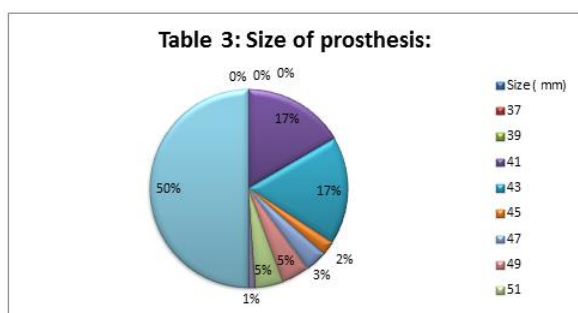
Age	Excellent	Good	Fair	Poor	Total
50-59	80	0	0	0	80
60-69	292	32	0	0	324
>=70	357	275	120	0	752
Total	729	307	120	0	1156



**Fig-2: Age v/s Results**

**Table-3: Size of prosthesis**

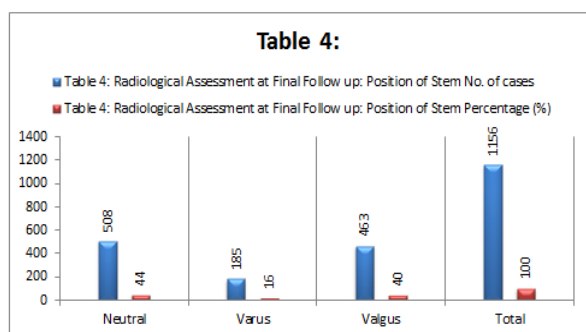
Size (mm)	Male	Female	Total	Percentage (%)
37	0	0	0	0
39	0	12	12	1
41	167	145	312	27
43	177	193	370	32
45	23	255	278	24
47	35	46	81	7
49	46	0	46	4
51	46	0	46	4
53	10	1	11	1
Total	504	652	1156	100



**Fig-3 Size of prosthesis**

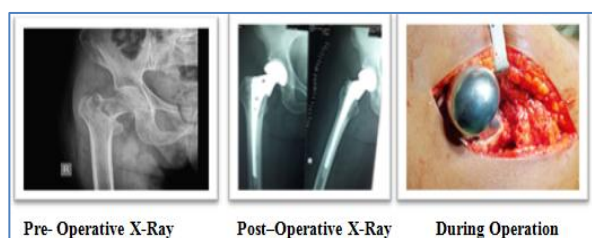**Table-4: Radiological Assessment at Final Follow up: Position of Stem**

Position of Stem	No. of cases	Percentage (%)
Neutral	508	44
Varus	185	16
Valgus	463	40
Total	1156	100

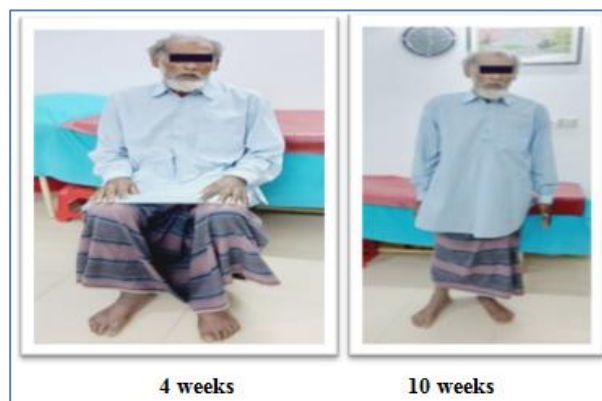

**Fig-4: Radiological Assessment at Final Follow up: Position of Stem**

**Clinical Photographs**



**Final Follow Up**



**DISCUSSION**

Elderly patients with fracture neck of femur who were mobile before injury should be able to restore to their preoperative functional and ambulatory status. The treatment of femoral neck fractures in elderly has always been controversial. Scanning the literature shows various views on the treatments, some advocate internal fixation and others prosthetic replacement, whether unipolar or bipolar. Lu-Yao et al in series of 106 cases found approximately threefold increase in reoperation if internal fixation was used compared to hemiarthroplasty for displaced femoral neck fractures in greater than 50 years old [9]. He had 33% nonunion and 16% avascular necrosis for patients treated with internal fixation. He found rate of re-operation was double when unipolar prosthesis is used. Lu - Yao et al. further substantiated that total hip replacement is another excellent procedure but as high dislocation rate of 10.7% [9]. Bavadekar and Manelkar (1987) feel that "In India the erratic and technically demanding procedures of total hip replacement will lack universal application for a long time to come and the Hemi replacement procedure will need to have continued application to fill the lacuna produced by deficient resources and finances..." In this context we undertook the present study to evaluate the results of hemiarthroplasty in fracture neck of femur keeping in view the social and economic condition of an average. Parker MJ et al. [11] had confirmed that cemented bipolar hemiarthroplasty patients had minimal pain, better mobility, and no significant difference in complications when compared with un-cemented bipolar hemi arthroplasty patients. Overall trend has fallen in favor of bipolar hemiarthroplasty due to early ambulation of elderly patient, most reliable and predictable outcomes and less failure rate as compared to internal fixation. Results for femoral neck fracture treatment illustrated by Leighton et al. [10] recommend prosthetic replacement for patients more than 60 years old having neck of femur fracture. Uncemented stems are to be considered in patients with significant cardiovascular risk factors and those who need total hip arthroplasty in the 'active elderly patient,' while unipolar prostheses (Moore or Thompson) are used only in minimally ambulatory

patients [10]. Torisu [13] reported the use of the bipolar implant with significant acetabular deficiency. At the end of 5 years there was no further migration of the head. In our study, due to minimal follow-up period, we were not able to report migration and acetabular erosion in any of our patients. Wilson and R.D. Scott [15] reported successful use of bipolar implant for reconstruction of deficient Acetabulum with acceptable relief of pain and good functional ability. In Bateman [14] series, there were some 70 hips converted from ankylosis to mobility. The average preoperative score was 45. The postoperative score was 82, with an average increment of 37. The use of a single assembly implant considerably facilitates this Procedure. Lestrangle *et al.* [17] had successfully used bipolar endoprosthesis in the treatment of unstable comminuted fractures. He concluded that the bipolar implant, cemented or uncemented, improves the results markedly. Primary arthroplasty had been especially useful in the treatment of unstable comminuted inter-trochanteric fractures, which occur in patients of more advanced age. Colwill *et al.* [16] concluded in their series of 88 cases in the elderly and debilitated that the overall results were gratifying. Garrahan and Madden [19] recommended the use of long stem in hips with displaced fractures of femoral neck. They reported no evidence of acetabular erosion or protrusioacetabuli. The three-point fixation of the long stem remained no secure within the femoral canal with a tendency to limit calcar stress. Nottage and McMaster [18] reported that bipolar prosthesis had significant advantages to fixed stem prosthesis for fractures and reconstruction of the hip. When cemented and cementless prostheses were compared no significant differences were found in patients pain, walking distances, need of support, limp or sitting in high or normal chair [21]. Lo *et al.* [20] found less thigh pain and higher Harris hip scores with patients treated with cemented prostheses. Our study is not without its own shortcomings. First, our duration of follow-up of 12 months is very less for assessment of the longevity and functional endurance of the prosthesis used and hence coming to definitive conclusions. Second, we have not evaluated the degree of intra-prosthetic motion at the inner-bearing at each follow-up. Such studies are complicated and beyond the facilities available at our Institution. Such studies are indicated because there are claims that the motion at the inner-bearing reduces over time and most prostheses behave as unipolar prostheses over a period of time. Third, in our study there was no significant evidence of any advantage and complications in cemented and uncemented bipolar prosthesis. Concluded that the bipolar implant, cemented or uncemented, improves the results markedly. Primary arthroplasty had been especially useful in the treatment of unstable comminuted inter-trochanteric fractures, which occur in patients of more advanced age. Colwill *et al.* [16] concluded in their series of 88 cases in the elderly and debilitated that the overall results were gratifying. Garrahan and Madden [19] recommended the use of

long stem in hips with displaced fractures of femoral neck. They reported no evidence of acetabular erosion or protrusioacetabuli. The three-point fixation of the long stem remained secure within the femoral canal with a tendency to limit calcar stress. Nottage and McMaster [18] reported that bipolar prosthesis had significant advantages to fixed stem prosthesis for fractures and reconstruction of the hip. When cemented and cementless prostheses were compared no significant differences were found in patients pain, walking distances, need of support, limp or sitting in high or normal chair [21]. Lo *et al.* [20] found less thigh pain and higher Harris hip scores with patients treated with cemented prostheses. Our study is not without its own shortcomings. First, our duration of follow-up of 12 months is very less for assessment of the longevity and functional endurance of the prosthesis used and hence coming to definitive conclusions. Second, we have not evaluated the degree of intra-prosthetic motion at the inner-bearing at each follow-up. Such studies are complicated and beyond the facilities available at our institution. Such studies are indicated because there are claims that the motion at the inner-bearing reduces over time and most prostheses behave as unipolar prostheses over a period of time. Third, in our study there was no significant evidence of any advantage and complications in cemented and uncemented bipolar prosthesis.

## CONCLUSION

We conclude that bipolar hemiarthroplasty is a good method to manage displaced femoral neck fractures in elderly. It has gained good popularity as treatment method for fracture neck femur in elderly population in whom chances of osteosynthesis is very less and it provides good functional outcomes allowing patients to achieve near normal life. The only complications encountered in our study were infection and dislocation, which is well within accepted norms.

## REFERENCES

1. Levine, I.S. (1996). Orthopaedic knowledge update - trauma. *Am Acad Orthop Surg*, 1:113-119.
2. Asnis, S. E., & Wanek-Sgaglione, L. (1994). Intracapsular fractures of the femoral neck. Results of cannulated screw fixation. *The Journal of bone and joint surgery. American volume*, 76(12), 1793-1803.
3. Rae, P. J., Hodgkinson, J. P., Meadows, T. H., Davies, D. R., & Hargadon, E. J. (1989). Treatment of displaced subcapital fractures with the Charnley-Hastings hemiarthroplasty. *The Journal of bone and joint surgery. British volume*, 71(3), 478-482.
4. Swinotkowski, M. F. Current Concepts Review Intracapsular Fractures of the Hip. *J Bone and Joint Strg*, 129-138.
5. Thompson, F. R. (1954). Two and a half years'experience with a vitallium intramedullary hip prosthesis. *JBJS*, 36(3), 489-500.

6. Moore, A.T. (1957). The self-looking metal hip prosthesis. *J Bone Joint Surg (Am)*, 39:811.
7. Batemann, J. E. (1974). Single-assembly total hip prosthesis; preliminary report. *Orthop. Digest*, 2, 15-22.
8. D'Arcy, J. O. H. N., & Devas, M. I. C. H. A. E. L. (1976). Treatment of fractures of the femoral neck by replacement with the Thompson prosthesis. *The Journal of bone and joint surgery. British volume*, 58(3), 279-286.
9. La-Yao, G. L., Keller, R. B., Littenberg, B., & Wennberg, J. E. (1994). Outcomes after displaced fractures of the femoral neck. A meta-analysis of one hundred and six published reports. *J Bone Joins Surg Am*, 76(1), 15-25.
10. Leighton, R. K., Schmidt, A. H., Collier, P., & Trask, K. (2007). Advances in the treatment of intracapsular hip fractures in the elderly. *Injury*, 38(3), 24-34.
11. Parker, M. J., Gurusamy, K. S., & Azegami, S. (2010). Arthroplasties (with and without bone cement) for proximal femoral fractures in adults. *Cochrane database of systematic reviews*, (6).
12. Arthroplasty. (1990). *Clin Orthop*, 251:113-118.
13. Torisu, T., Utsunomiya, K., Maekawa, M. A. S. A. Y. U. K. I., & Ueda, Y. (1990). Use of bipolar hip arthroplasty in states of acetabular deficiency. *Clinical orthopaedics and related research*, (251), 119-125.
14. Bateman, J. E., Berenji, A. R., Bayne, O. M. A. R., & Greyson, N. D. (1990). Long-term results of bipolar arthroplasty in osteoarthritis of the hip. *Clinical orthopaedics and related research*, (251), 54-66.
15. Wilson, M. G., & Scott, R. D. (1990). Reconstruction of the deficient acetabulum using the bipolar socket. *Clinical orthopaedics and related research*, (251), 126-133.
16. LaBelle, L. W., Colwill, J. C., & Swanson, A. B. (1990). Bateman bipolar hip arthroplasty for femoral neck fractures. A five-to ten-year follow-up study. *Clinical orthopaedics and related research*, (251), 20-25.
17. Lestrang, N. R. (1990). Bipolar arthroplasty for 496 hip fractures. *Clinical orthopaedics and related research*, (251), 7-19.
18. NoTTAGE, W. M., & McMaster, W. C. (1990). Comparison of bipolar implants with fixed-neck prostheses in femoral-neck fractures. *Clinical orthopaedics and related research*, (251), 38-43.
19. Garrahan, W. F., & Madden, E. J. (1990). The long-stem bipolar prosthesis in surgery of the hip. *Clinical orthopaedics and related research*, (251), 31-37.
20. Lo, W. H., Chen, W. M., Huang, C. K., Chen, T. H., Chiu, F. Y., & Chen, C. M. (1994). Bateman bipolar hemiarthroplasty for displaced intracapsular femoral neck fractures. Uncemented versus cemented. *Clinical orthopaedics and related research*, (302), 75-82.
21. Sarvilinna, R., Pajamäki, J., Sovelius, R., Puolakka, T., Huhtala, H., & Järvinen, M. (2002). Bipolar hemiarthroplasty in the treatment of hip fracture: Are special centres necessary for the optimal outcome?. *Scandinavian journal of surgery*, 91(2), 182-185.